Git practical 1

Tongue

lamina propria

Neuroepithelial taste cell

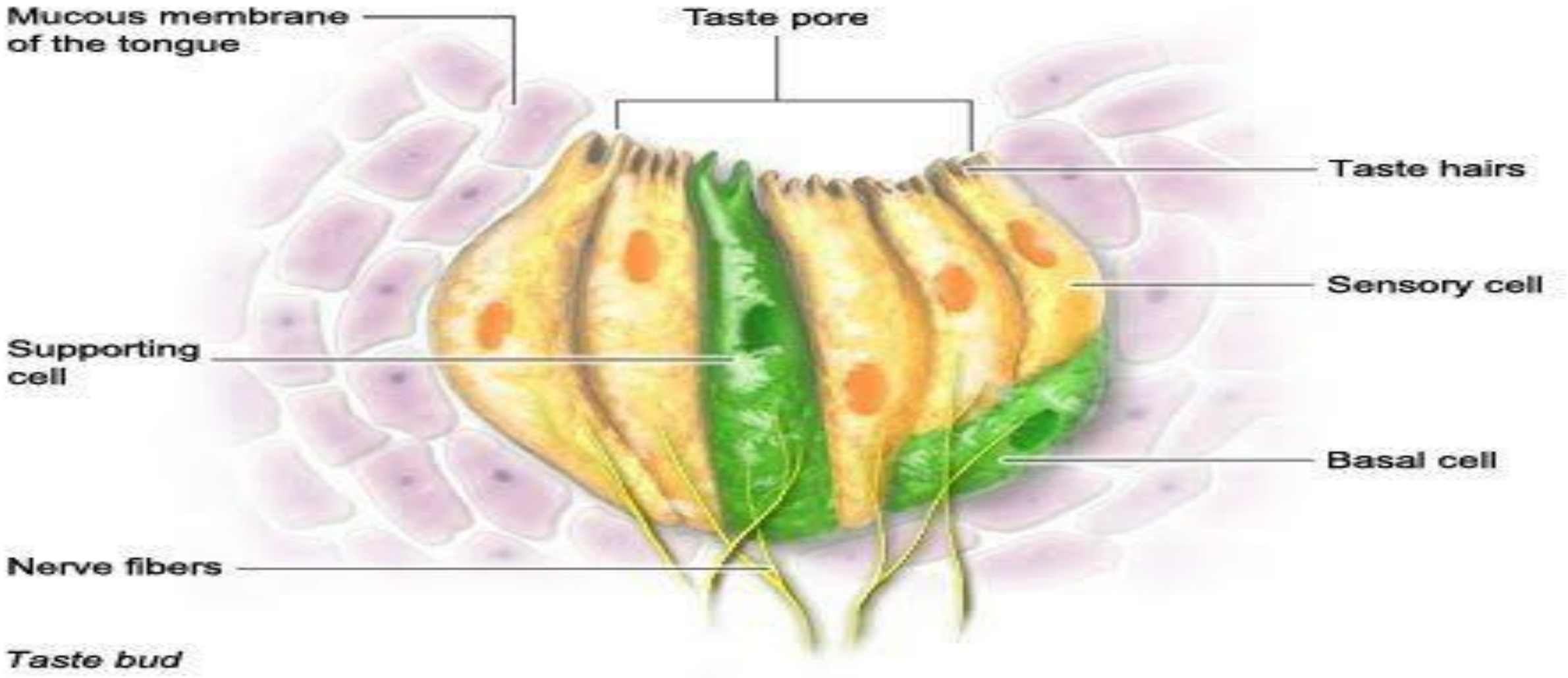

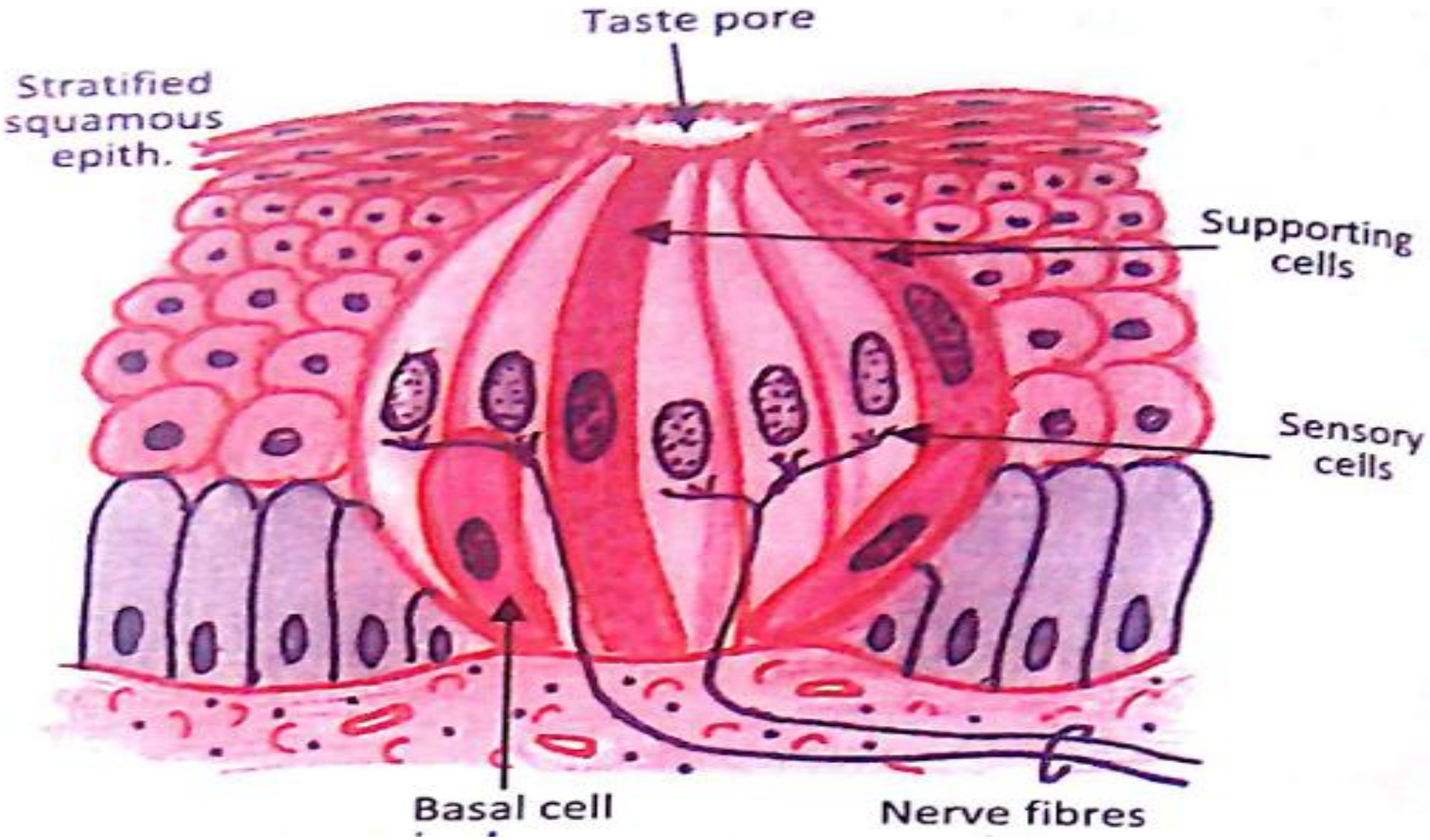
Taste pore
Stratified squamous epith.
Supporting cells
Sensory cells
Basal cell
Nerve fibres

Lips

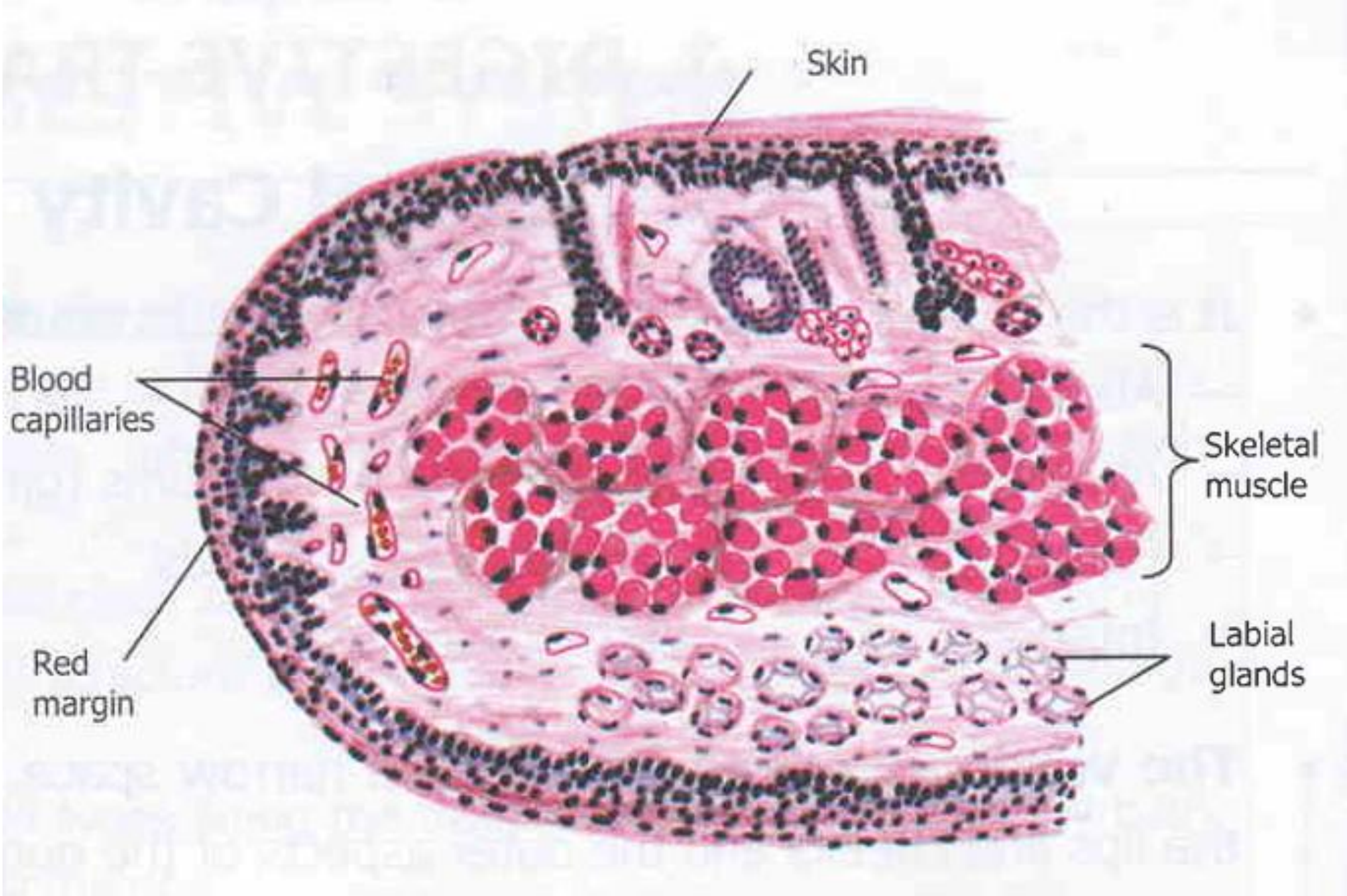
Skin
Blood capillaries
Skeletal muscle
Red margin
Labial glands

Esophagus

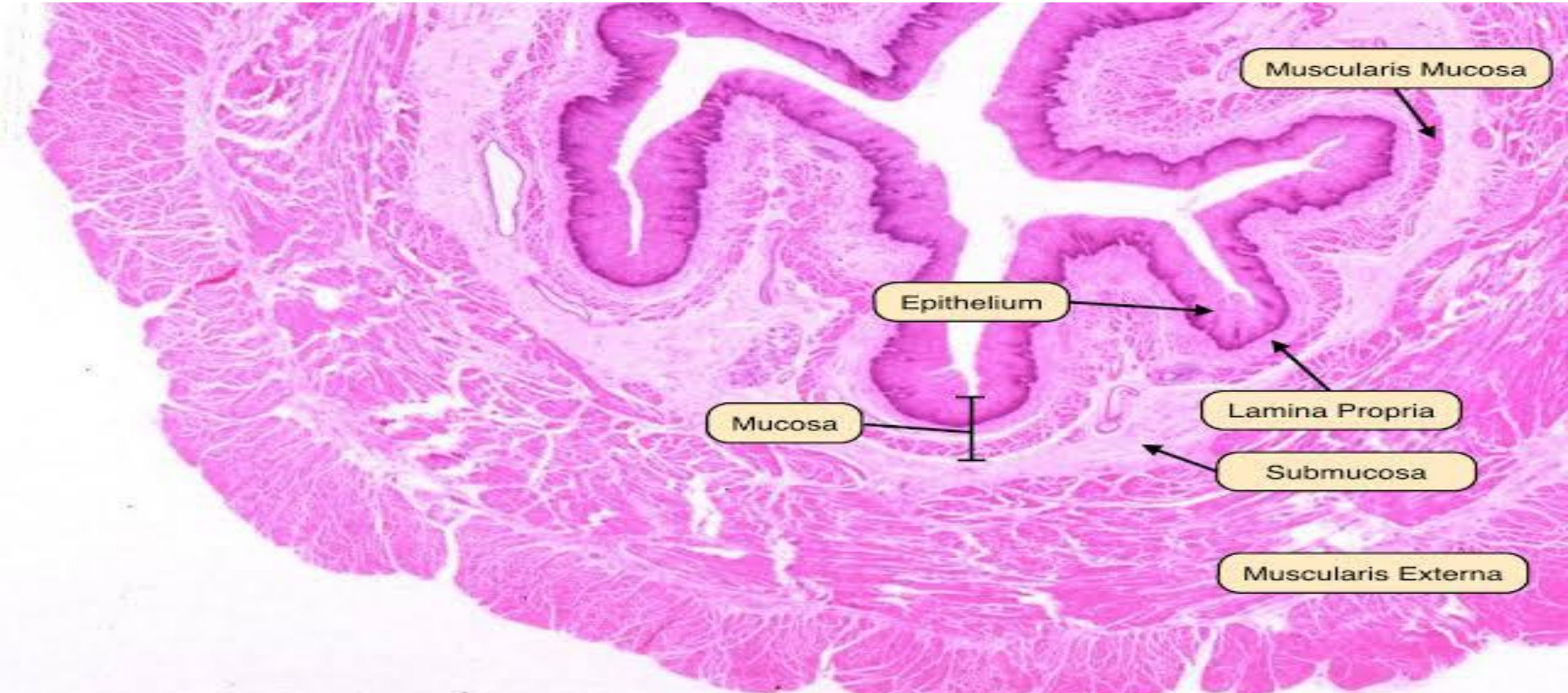
Muscularis Mucosa
Epithelium
Lamina Propria
Mucosa
Submucosa
Muscularis Externa

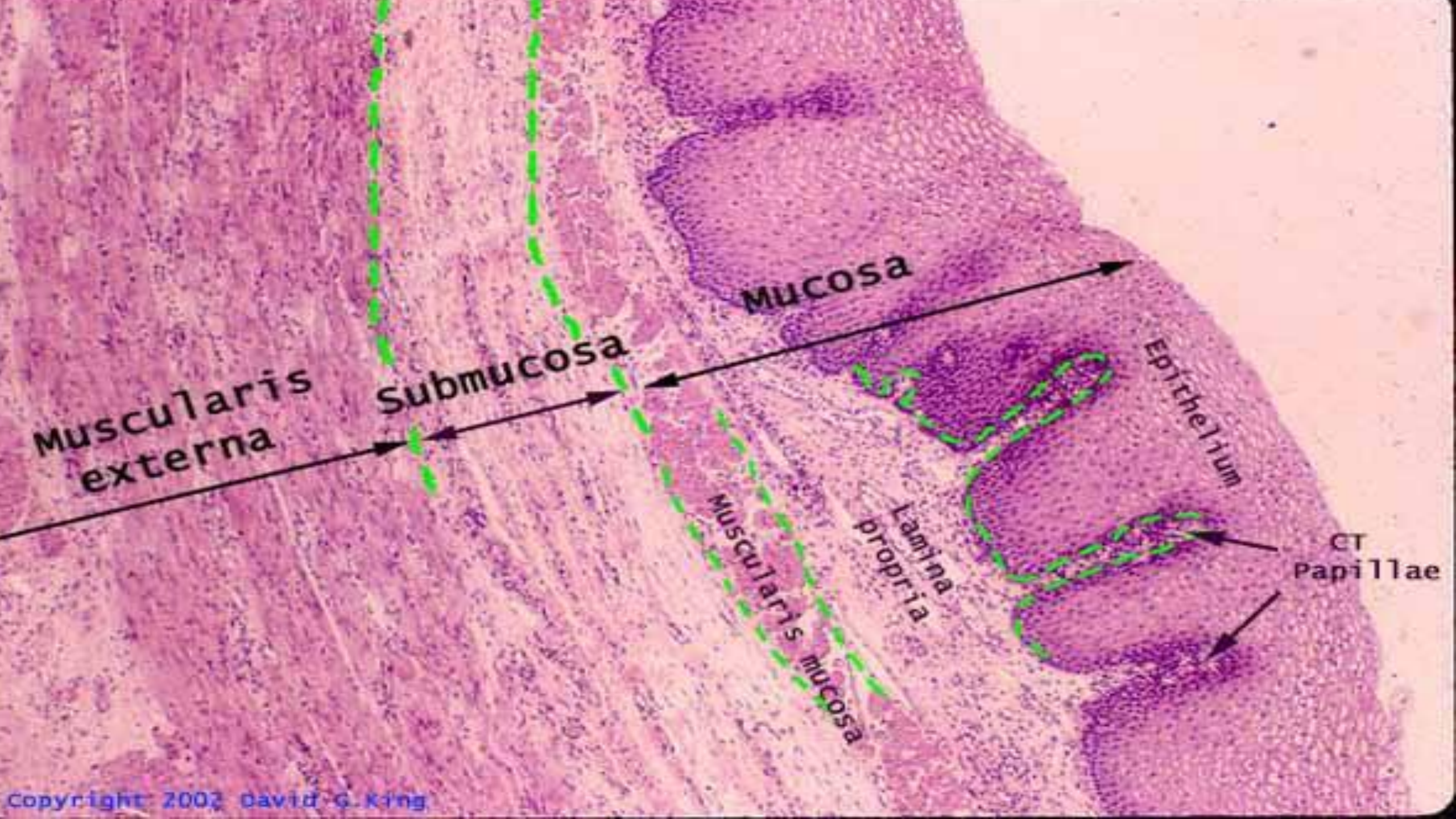
Muscularis externa
Submucosa
Mucosa
Epithelium
CT Papillae
Lamina propria
Muscularis mucosa
Copyright 2002 David G. King

Fundus

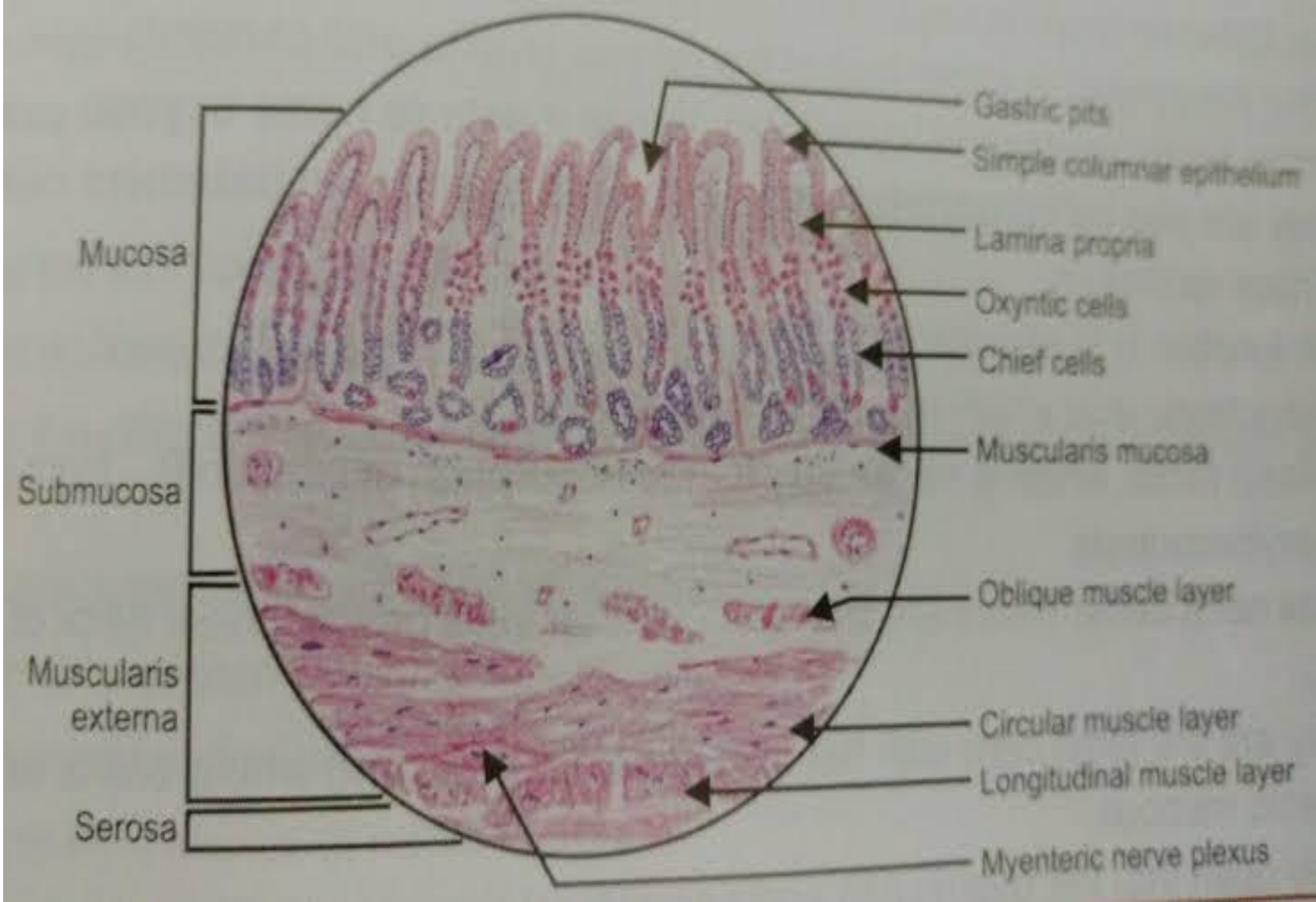
Mucosa
Submucosa
Muscularis externa
Serosa
Gastric pits
Simple columnar epithelium
Lamina propria
Oxyntic cells
Chief cells
Muscularis mucosa
Oblique muscle layer
Circular muscle layer
Longitudinal muscle layer
Myenteric nerve plexus

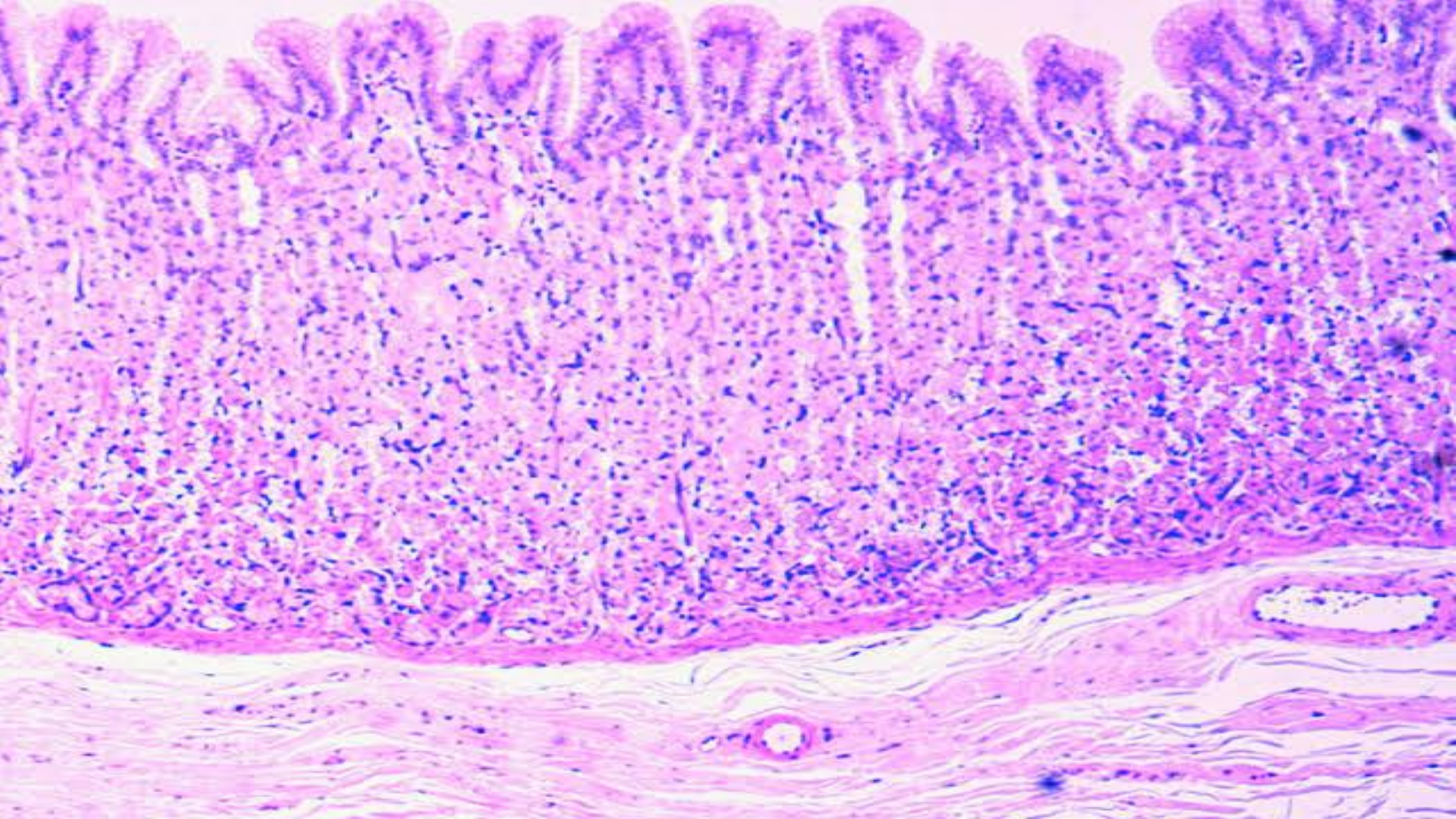

Pylorus

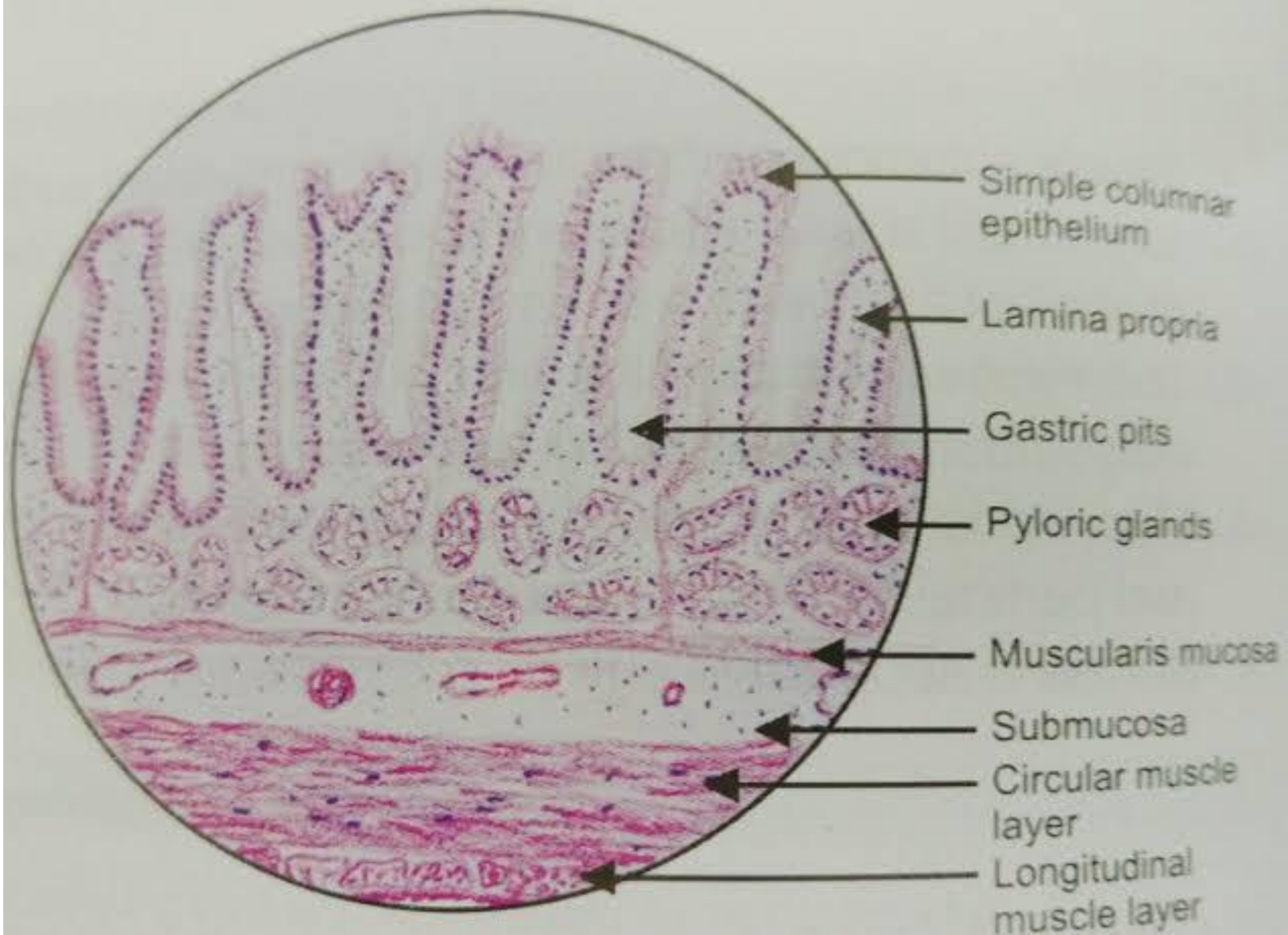
Simple columnar epithelium
Lamina propria
Gastric pits
Pyloric glands
Muscularis mucosa
Submucosa
Circular muscle layer
Longitudinal muscle layer

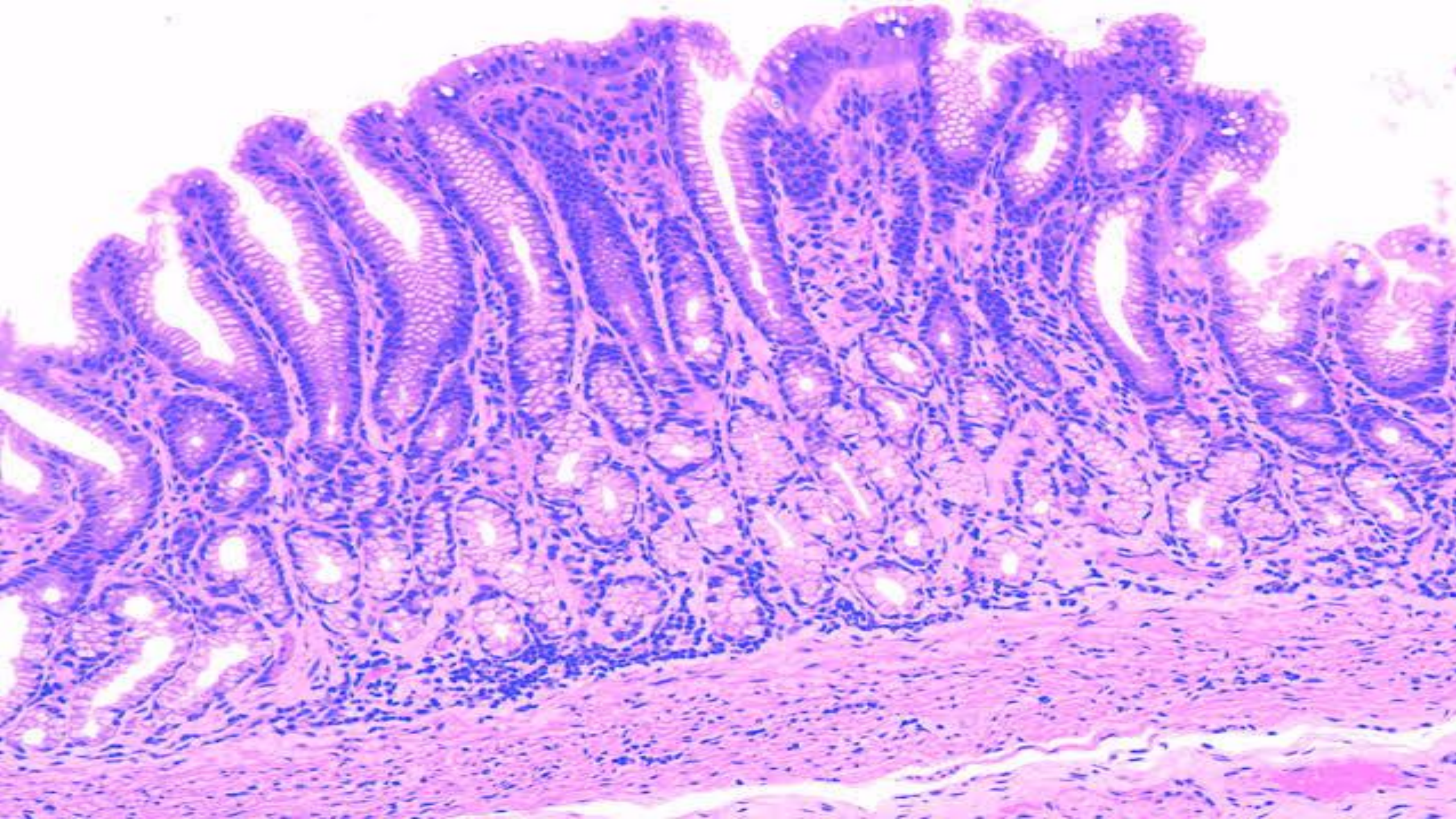

Chief (peptic) cell

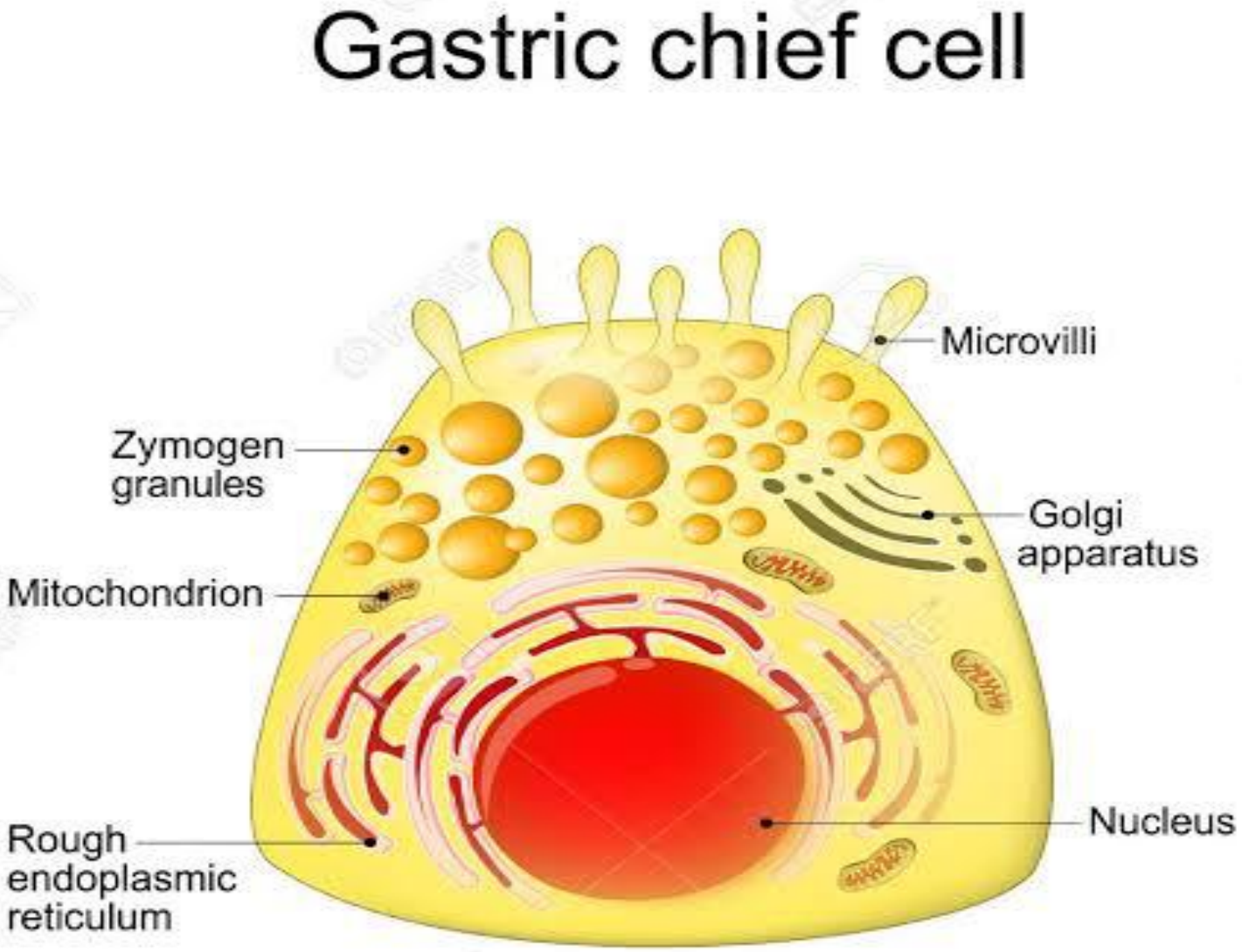

Parietal (oxyntic) cell

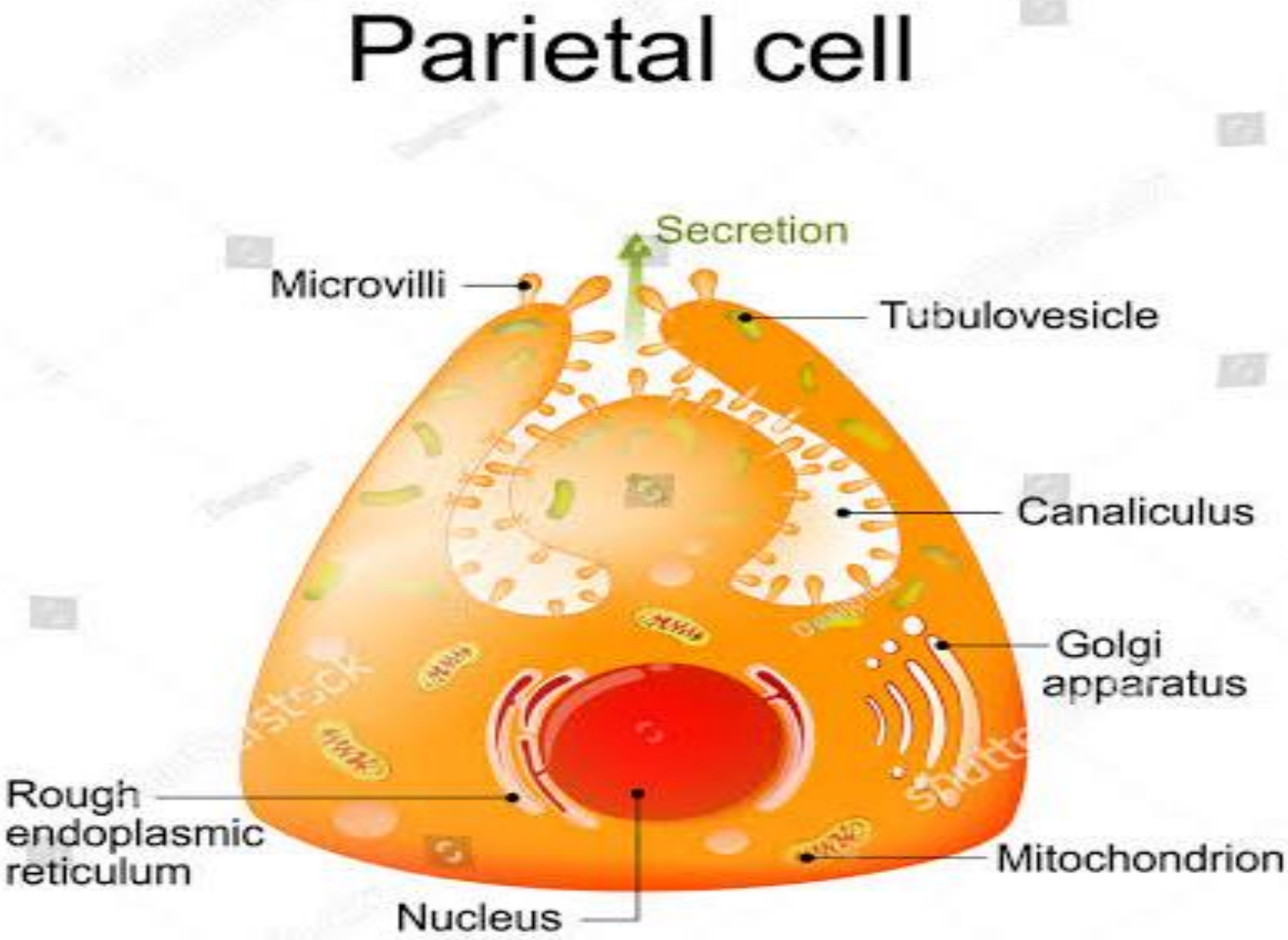
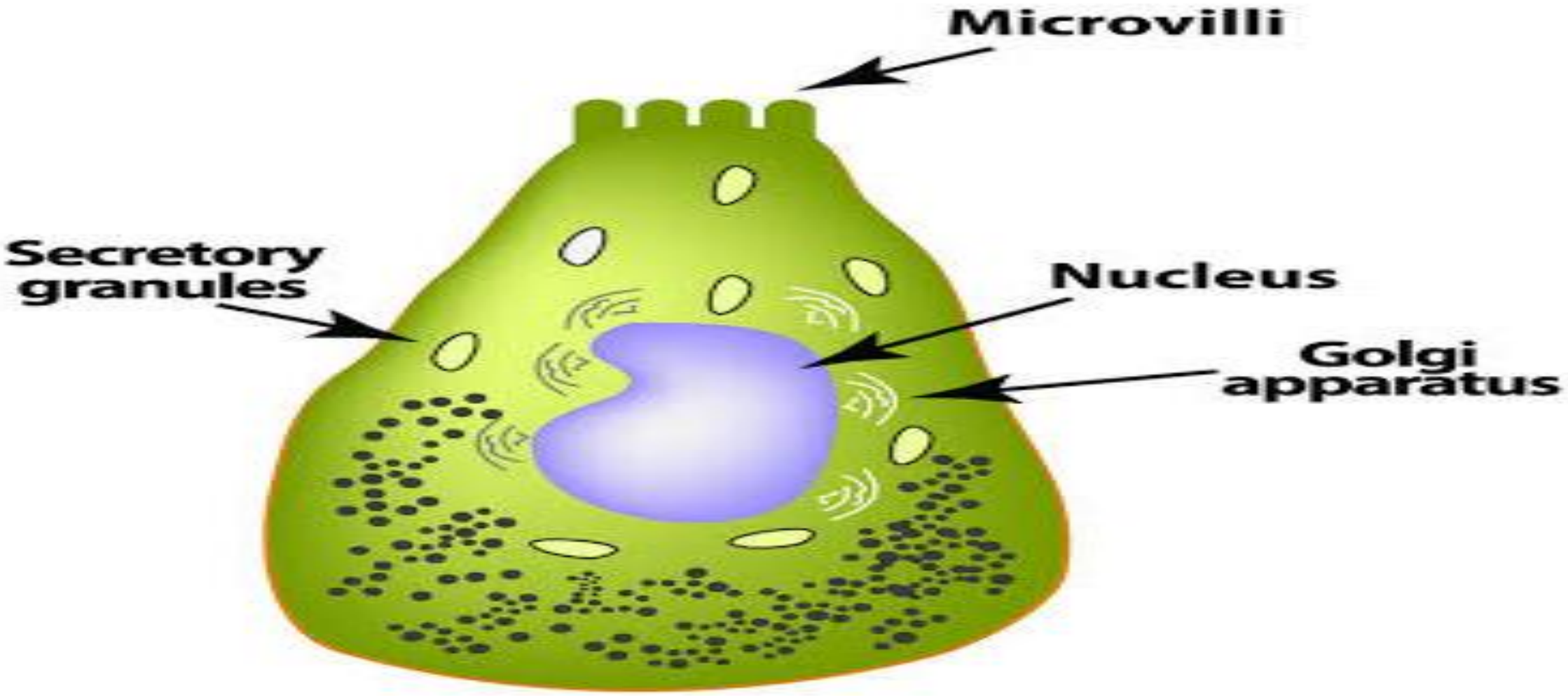
ENTEROENDOCRINE CELL